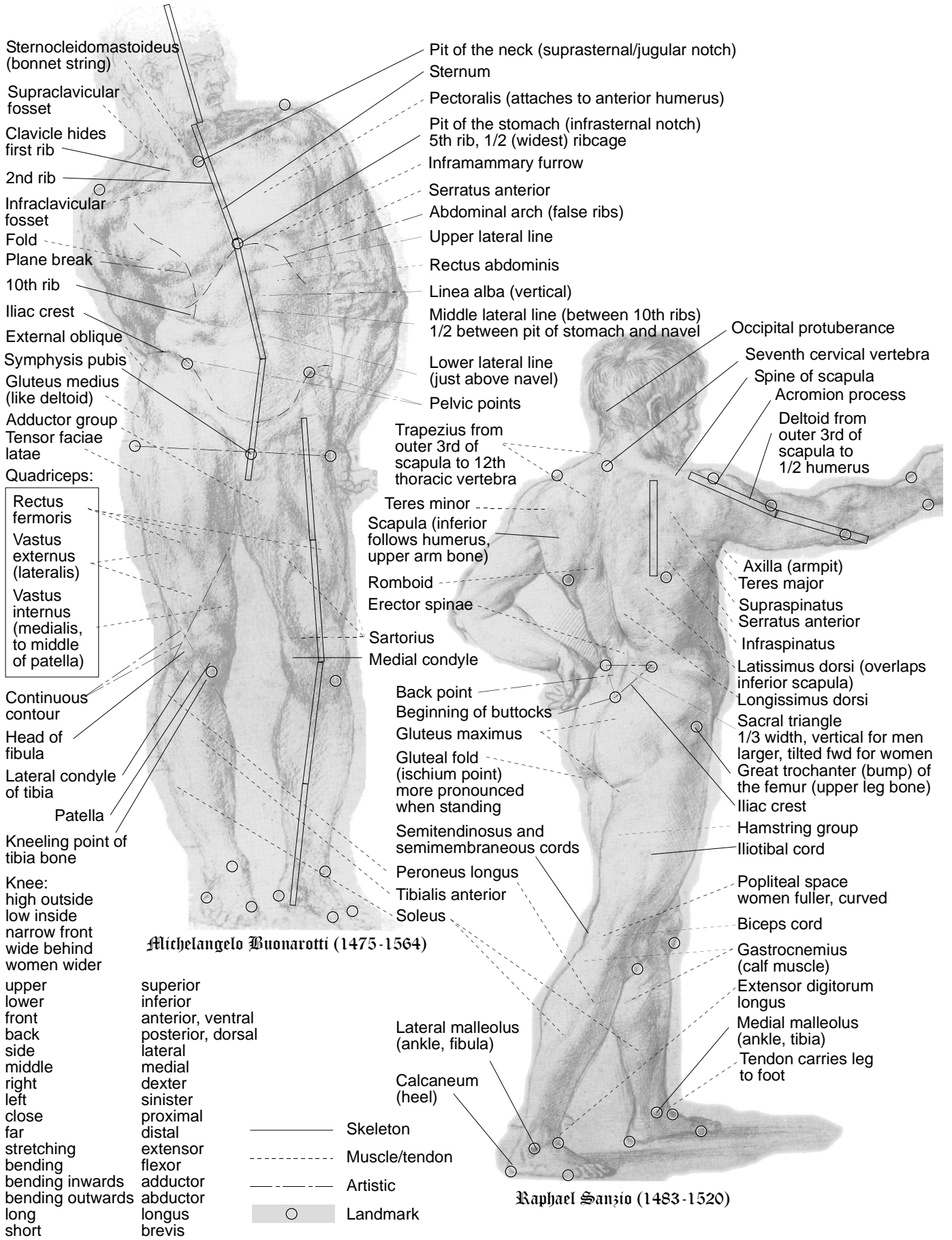


# Artistic Anatomy 1

© 2005 Sven Trebard



Sternocleidomastoideus (bonnet string)  
 Supraclavicular fosset  
 Clavicle hides first rib  
 2nd rib  
 Infraclavicular fosset  
 Fold  
 Plane break  
 10th rib  
 Iliac crest  
 External oblique  
 Symphysis pubis  
 Gluteus medius (like deltoid)  
 Adductor group  
 Tensor faciae latae  
 Quadriceps:  
 Rectus femoris  
 Vastus externus (lateralis)  
 Vastus internus (medialis, to middle of patella)  
 Continuous contour  
 Head of fibula  
 Lateral condyle of tibia  
 Patella  
 Kneeling point of tibia bone  
 Knee:  
 high outside  
 low inside  
 narrow front  
 wide behind  
 women wider  
 upper  
 lower  
 front  
 back  
 side  
 middle  
 right  
 left  
 close  
 far  
 stretching  
 bending  
 bending inwards  
 bending outwards  
 long  
 short

Michelangelo Buonarroti (1475-1564)

Pit of the neck (suprasternal/jugular notch)  
 Sternum  
 Pectoralis (attaches to anterior humerus)  
 Pit of the stomach (infrasternal notch)  
 5th rib, 1/2 (widest) ribcage  
 Inframammary furrow  
 Serratus anterior  
 Abdominal arch (false ribs)  
 Upper lateral line  
 Rectus abdominis  
 Linea alba (vertical)  
 Middle lateral line (between 10th ribs)  
 1/2 between pit of stomach and navel  
 Lower lateral line (just above navel)  
 Pelvic points  
 Trapezius from outer 3rd of scapula to 12th thoracic vertebra  
 Teres minor  
 Scapula (inferior follows humerus, upper arm bone)  
 Romboid  
 Erector spinae  
 Sartorius  
 Medial condyle  
 Back point  
 Beginning of buttocks  
 Gluteus maximus  
 Gluteal fold (ischium point) more pronounced when standing  
 Semitendinosus and semimembraneous cords  
 Peroneus longus  
 Tibialis anterior  
 Soleus  
 Lateral malleolus (ankle, fibula)  
 Calcaneum (heel)

Occipital protuberance  
 Seventh cervical vertebra  
 Spine of scapula  
 Acromion process  
 Deltoid from outer 3rd of scapula to 1/2 humerus  
 Axilla (armpit)  
 Teres major  
 Supraspinatus  
 Serratus anterior  
 Infraspinatus  
 Latissimus dorsi (overlaps inferior scapula)  
 Longissimus dorsi  
 Sacral triangle  
 1/3 width, vertical for men  
 larger, tilted fwd for women  
 Great trochanter (bump) of the femur (upper leg bone)  
 Iliac crest  
 Hamstring group  
 Iliotibial cord  
 Popliteal space  
 women fuller, curved  
 Biceps cord  
 Gastrocnemius (calf muscle)  
 Extensor digitorum longus  
 Medial malleolus (ankle, tibia)  
 Tendon carries leg to foot

Raphael Sanzio (1483-1520)

- Skeleton
- - - Muscle/tendon
- - - Artistic
- Landmark